

Intracapsular Prostatic Omentalization: A New Technique for Management of Prostatic Abscess in Dogs: Case Report

Adel Aissi



CrossMark
click for updates

DOI: 10.18869/IJABBR.2018.35

International Journal of Advanced Biological and Biomedical Research

Journal DOI: 10.18869/IJABBR

ISSN: 2322-4827

CODEN (USA): IJABIS

<http://ijabbr.com>



Copyright © 2018 by authors and CASRP Publishing Company, Ltd, UK. This work is licensed under the Creative Commons Attribution International License (CC BY4.0).

<https://creativecommons.org/licenses/by/4.0/>



Available online at <http://ijabbr.com>

CASRP PUBLISHER

**International Journal of Advanced Biological
and Biomedical Research 7(1) (2018) 35–38**

doi: 10.18869/IJABBR.2018.35



Case Report

Open Access

Intracapsular Prostatic Omentalization: A New Technique for Management of Prostatic Abscess in Dogs: Case Report

Adel Aissi*

Surgery and Veterinary Imaging Service, Veterinary Institute, Batna University, Algeria.

Abstract

There are many techniques have been used in the surgical treatment of prostatitis, prostatic abscesses and prostatic cysts. Partial or complete prostatectomy, marsupialization, or debridement and drainage have all been advocated; unfortunately all of these techniques are associated with complications such as incontinence, cyst or abscess recurrence, etc. More recently, prostatic omentalization has been described. In this procedure, after opening and draining any cystic cavities or abscesses within the prostate, a portion of the omentum is passed through the prostate by blunt dissection. This improves the vascular supply to the affected tissue and prevents re-formation of a closed cystic/abscess cavity. It is very effective in preventing recurrence of disease. In this paper, we will describe omentalization of the prostate.

© 2018 Published by CASRP Publishing Company Ltd. UK. Selection and/or peer-review under responsibility of Center of Advanced Scientific Research and Publications Ltd. UK.

Keywords: Dog, Prostate, Cavity, Omentalization

1. Introduction

The prostate is the only male sexual accessory gland. Its main role is the secretion of prostatic fluid, which constitutes the major part of the volume of ejaculated sperm. The prostate develops under the control of testosterone, the hormone produced by the testicles and adrenal glands. The prostate becomes more and more sensitive to this hormone.

*Corresponding author: adelaissi050@gmail.com

© 2018 The Authors. This is an open access article under the terms of the Creative Commons Attribution-Non Commercial- No Derives License, which permits use and distribution in any medium, provided the original work is properly cited, the use is non-commercial and no modifications or adaptations are made.

Received 19 January 2018

iThenticate screening 22 January 2018

Accepted 20 May 2018

English editing 18 May 2018

Available online 30 May 2018

Quality control 28 May 2018

Under the hormonal influence the prostate undergoes physiological and sometimes pathological changes. In the elderly dog the prostate is the site of many affections on the one hand benign as prostatic hyperplasia and on the other hand serious, cysts, abscesses and more rare prostatic adenocarcinomas. It is therefore interesting to know these prostatic conditions, in order to better detect and offer the best treatment.

Clinical signs in dogs with prostate pathology include systemic signs such as fever, depression, anorexia, weakness, depression, weight loss, gastrointestinal signs (constipation, rectal tenesmus) and locomotors (arched back, stiffness of the hind legs, A balanced gait, and a purulent and blood flow at the end of the penis are often frequent. Transrectal exploration of the prostate is often very painful (Klausner et al., 1995; Fontbonne, 2007; Root-Kusritz et al., 2000; Smith, 2008).

2. Case presentation

2.1. Case history

A seven year male cross breed dog was presented to surgery and veterinary imaging service at the Batna University with expiratory dyspnea; vomiting, abdominal palpation was painful. An intra-abdominal mass, hard and at the level of the sheath was diagnosed. The temperature, pulse and respiration were 40.3 C, 91/min, 19/min respectively and purulent urethral discharge associate with rectal palpation of prostate elicited pain.

2.1.1. Radiology

Radiographic examination of the pelvic lateral region characterized by an increase in prostatic volume is great than 70% of the pubicsacral promontory distance (Finn, 1989; Fontbonne et al., 2007) (Fig. 1).

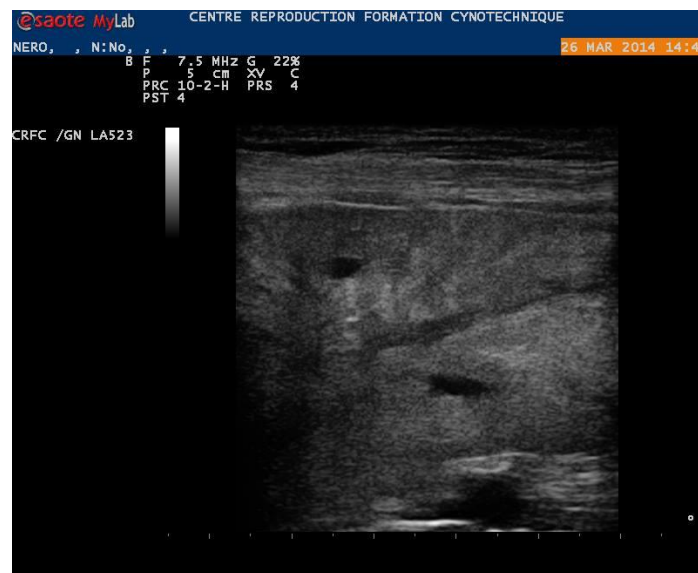

Fig. 1. Ultrasonography of prostate reveals the presence of two cavity variables.

2.1.2. Ultrasound

Demonstrate an increase in prostatic volume with modification echogenicity of prostatic parenchyma. The prostate reveals the presence of two cavity variables anechoic or hypoechoic of variable size (Fig. 1), delimited by a thin wall with posterior reinforcement (Finn et al., 1995; Nyland, 2002; Keally, 2005). Trans-abdominal ultrasonography fine needle aspiration biopsy (FNAB) shows the presence of pus in the cavities (Fig. 2).

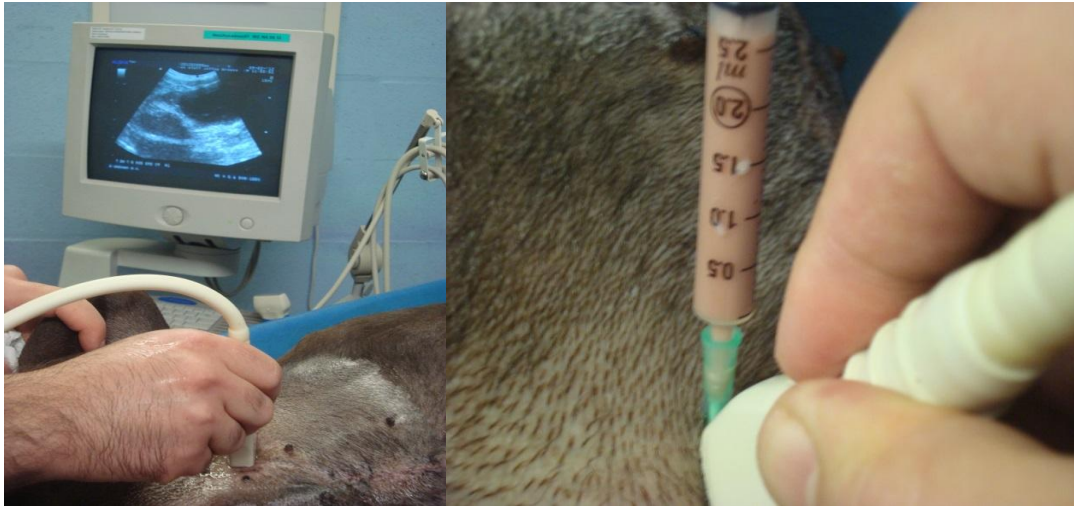


Fig. 2. Trans- abdominal ultrasonography fine needle aspiration biopsy (FNAB).

2.1.3. Surgical treatment

Access to the prostate is usually achieved through a midline incision of the caudoventral abdomen. A perineal approach has also been described. The prostate is exposed and isolated from surrounding tissue using moist laparotomy sponges (Johnston, 2000). In some instance spathogenic tissue, provides lymphatic drainage, and minimizes the formation of postoperative adhesions by covering surgically created lesions. Omentalization is the current treatment of choice for cavity lesions and urethral laceration, the omentum is placed into the prostate around or along the prostatic urethra (Fig. 3). After caudal celiotomy and exposure of the prostate, intracapsular abscesses or cysts are approached through a bilateral stab incision into the ventral prostatic capsule. The dorsolateral prostatic tissue should be avoided to minimize the risk for damage to the neurovascular supply (Salomon, 2006). The lesions are debrided by digital manipulation, suction, and lavage. During debridement, damage to the prostatic urethra may be avoided by palpation of the preoperatively placed catheter. After debridement, the prostatic capsule is unilaterally resected to create an opening for the omentum Fig. 4. A tissue forceps is passed through the contralateral incision to grasp the omentum. The omentum is drawn through the capsulectomy site and around the urethra. The omental pedicle is then grasped and sutured to the omentum at the entry site.

2.1.4. Postoperative care

1. Broad spectrum antibiotics for 5-7 days postoperatively. 2. In most cases the urinary catheter is removed immediately postop. It may be maintained, with a closed collection set, in dogs that are severely dysuric. 3. Drain removal 3-4 days postoperatively.

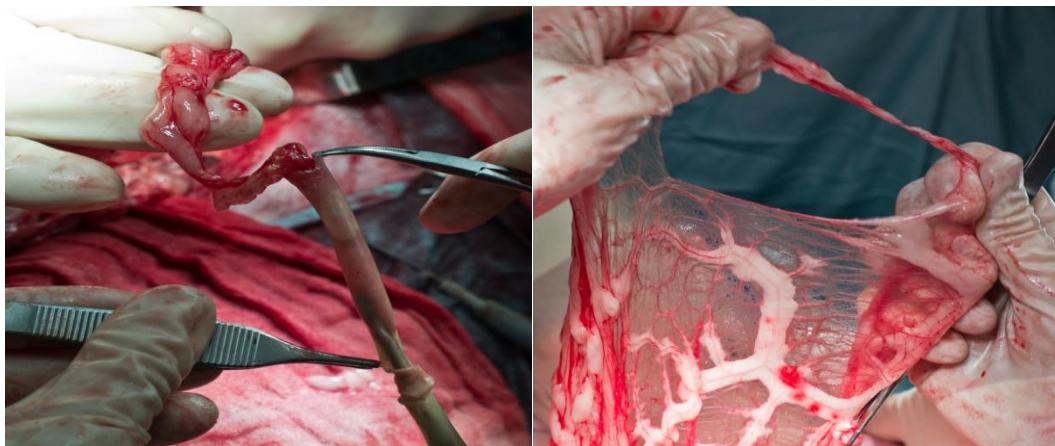


Fig. 3. Omentum surgical preparation.

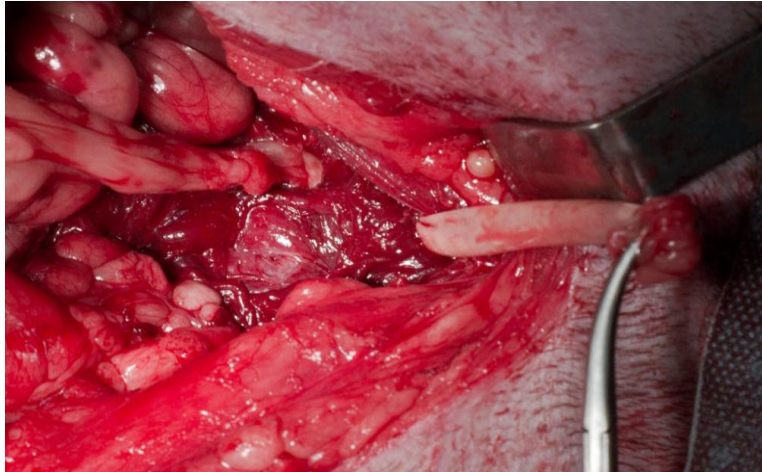


Fig. 4. Prostate omentalization.

References

- Finn, S.T., Wrigley, R.H., 1989. Ultrasonography and ultrasound-guided biopsy of the canine prostate. In: Kirk, R.W., Current veterinary therapy X. Small animal practice. Philadelphia, W.B. Saunders Company, 1227-1239.
- Fontbonne, A., Levy, X., Fontaine, E., Gilson, C., 2007. Techniques chirurgicales. In: Guide pratique de reproduction clinique canine et féline, Med'com, Paris, 231-240.
- Johnston, S.D., Kamolpatana, K., Root-Kustritz, M.V., Johnston, G.R., 2000. Prostatic disorders in the dog. Anim. Reprod. Sci., 60-61, 405-415.
- Keally, J., 2005. The prostate gland. In: diagnostic radiology and ultrasonography of the dog and cat, 4thed., Elsevier Saunders, Saint Louis, 149-156.
- Klausner, J.S., Johnston, S.D., Bell, F.W., 1995. Canine prostatic disorders. In: Bonagura, J.D., Kirk, R.W., Current Veterinary Therapy XII. Small animal practice. Philadelphia, WB Saunders Company, 1103-1108.
- Nyland, T.G., 2002. Prostate and testes. In: small animal diagnostic ultrasound, 2nded., Philadelphia, WB Saunders Company, 250-259.
- Root-Kustritz, M.V., Klausner, J.S., 2000. Prostatic diseases. In: Ettinger, S.J., Feldman, E.C., Textbook of Veterinary Internal Medicine. Diseases of the Dog and Cat. Philadelphia, WB Saunders Company. 2, 1687-1698.
- Salomon, J.F., 2006. Chirurgie de la prostate chez le chien. Biopsie, drainage et exérèse de la prostate. Point vét. 37, N° spécial: Chirurgie abdominale chez le chien et le chat, 102-105.

How to cite this article: Aissi, A., 2018. Intracapsular Prostatic Omentalization: A New Technique for Management of Prostatic Abscess in Dogs: Case Report. International Journal of Advanced Biological and Biomedical Research, 7(1), 35-38.

Submit your next manuscript to CASRP Central and take full advantage of:

- Convenient online submission
- Thorough peer review
- No space constraints or color figure charges
- Immediate publication on acceptance
- Inclusion in Google Scholar
- Research which is freely available for redistribution

Submit your manuscript at
<http://ijabbr.com>

